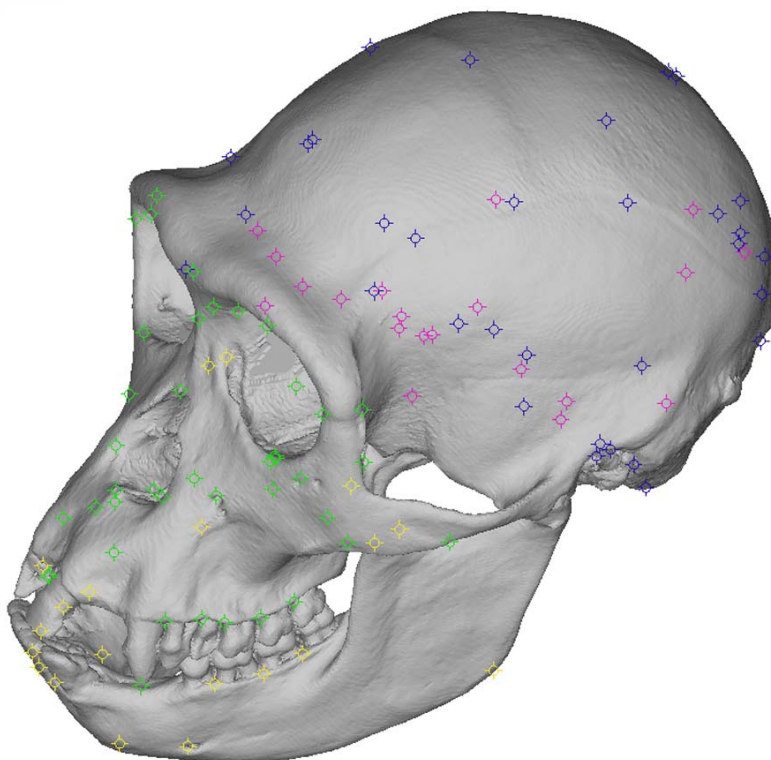


We quantified the 3D coordinates of a long list of landmarks (N=116) on the skull and mandible of #9338, including landmarks that are frequently used in studies of craniofacial morphology of great apes. The landmarks were positioned on the 3D model with ArteCore. The original CT data were also used to valid or to help to identify the location of landmarks. The landmarks characterize the face (N=43; landmarks in green on the figure), the mandible (N=20; in yellow), the calvaria (N=33; in blue) and the endocranial surface (N=20) of the type specimen of *Pan paniscus*.



Landmarks name	Definitions
On the calvaria	
AsterionL	Point on the external surface of the skull where the lambdoid, parietomastoid and occipitomastoid sutures meet, left side.
AsterionR	Point on the external surface of the skull where the lambdoid, parietomastoid and occipitomastoid sutures meet, right side.
Basion	Midpoint of the anterior border of the foramen magnum in the median plane.
BLmidproj	Ectocranial midline point resulting from the projection of the middle point of the chord from bregma to lambda.
Bregma	Point on the surface of the skull at the junction of the coronal and sagittal sutures.
ExternalOccipitalProtuberance	Posterior extension of the prominence at the centre of the outer surface of the squama of the occipital bone which gives attachment to the ligamentum nuchae.
GBmidproj	Ectocranial midline point resulting from the projection of the middle point of the chord from glabella to bregma.
Glabella	Most anterior midline point on the frontal bone at the level of the supraorbital torus.
Inion	Midline point at the level of the uppermost extension of the superior nuchal line.
Lambda	Point on the external surface of the skull where the lambdoid and sagittal sutures meet.
MastoidalL	Lowest point of the mastoid process, left side.
MastoidalR	Lowest point of the mastoid process, right side.

MastTympanalL	Junction between the tympanal and the mastoid process, left side.
MastTympanalR	Junction between the tympanal and the mastoid process, right side.
Metopion	Ectocranial midline point on frontal as its greatest elevation relative to the chord from nasion to bregma.
OccipitalCondyleLatL	Most lateral point on the occipital condyle, left side.
OccipitalCondyleLatR	Most lateral point on the occipital condyle, right side.
Opisthion	Point located at the midpoint of the posterior border of the foramen magnum.
Opisthocranion	Point determined instrumentally to indicate the posterior end of the maximum cranial length measured along the midline of the glabella.
Parietopion	Midline ectocranial point at the greatest elevation above the chord from bregma to lambda.
PorionL	Point, being the most lateral point on the roof of the bony external acoustic meatus, vertically over the middle of the meatus, left side.
PorionR	Point, being the most lateral point on the roof of the bony external acoustic meatus, vertically over the middle of the meatus, right side.
PostOrbConstrTalLineL	Most medial point on the upper temporal line in the area of the postorbital constriction, left side.
PostOrbConstrTalLineR	Most medial point on the upper temporal line in the area of the postorbital constriction, right side.
postTemporalLineL	Most posterior point on the upper temporal line, left side.
postTemporalLineR	Most posterior point on the upper temporal line, right side.
StephanionL	Point on the side of the cranium at which the coronal suture meets the superior temporal line, left side.
StephanionR	Point on the side of the cranium at which the coronal suture meets the superior temporal line, right side.
StylomastoidForamenAntL	Most anterior point on the border of the stylomastoid foramen, left side.
StylomastoidForamenAntR	Most anterior point on the border of the stylomastoid foramen, right side.
summitOalreliefL	Higher point in posterior view of the superior nuchal line, left side.
summitOalreliefR	Higher point in posterior view of the superior nuchal line, right side.
SupraGlabellar	Deepest point of the depression behind the glabella in the median plane.

On the endocranial surface

AntClinoidProcessPostL	Most posterior point on the anterior clinoid process, left side.
AntClinoidProcessPostR	Most posterior point on the anterior clinoid process, right side.
Endinion	Point in the median plane at the junction of the sagittal and lateral sinuses.
ForamenCaecum	Most anterior inferior point of anterior cranial base.
FrontalPoleL	Most anterior prominent point on the frontal lobe, left side.
FrontalPoleR	Most anterior prominent point on the frontal lobe, right side.
HypoglossalCanalL	Most anterior point on the border of the hypoglossal canal, left side.
HypoglossalCanalR	Most anterior point on the border of the hypoglossal canal, right side.
InternalAuditoryMeatusPostL	Most posterior point on the border of the internal auditory meatus, left side.
InternalAuditoryMeatusPostR	Most posterior point on the border of the internal auditory meatus, right side.
OccipitalPoleL	Most posterior prominent point on the occipital lobe, left side.
OccipitalPoleR	Most posterior prominent point on the occipital lobe, right side.

OpticForamenSupL	Most antero-lateral point on the upper border of the optic foramen, left side.
OpticForamenSupR	Most antero-lateral point on the upper border of the optic foramen, right side.
SellaTurcica	Point at the centre of the sella turcica.
SigmoidSupL	Most superior point on the sigmoid sinus, left side.
SigmoidSupR	Most superior point on the sigmoid sinus, right side.
Sphenoidale	Most superior and posterior midline point on the tuberculum sellae.
TemporalPoleL	Most anterior prominent point on the temporal lobe, left side.
TemporalPoleR	Most anterior prominent point on the temporal lobe, right side.

On the face

Acanthion	Point at the tip of the anterior nasal spine.
AlareL	Most lateral point on the border of the nasal aperture, left side.
AlareR	Most lateral point on the border of the nasal aperture, right side.
Ectochoinchion-zygofrontalL	Point where zygofrontal suture intersects orbital margin, left side.
Ectochoinchion-zygofrontalR	Point where zygofrontal suture intersects orbital margin, right side.
FrontoZygoTalLineL	Point where zygofrontal suture intersects the course of the temporal lines, left side.
FrontoZygoTalLineR	Point where zygofrontal suture intersects the course of the temporal lines, right side.
GreaterPalatineForamenL	Most posterior point on the border of the greater palatine foramen, left side.
GreaterPalatineForamenR	Most posterior point on the border of the greater palatine foramen, right side.
IncisiveCanal	Most anterior and inferior midline point of incisive canal on the hard palate.
InferiorPterygoPalatinL	Most inferior point of the area where the palatine and the lateral pterygoid plate meet, left side.
InferiorPterygoPalatinR	Most inferior point of the area where the palatine and the lateral pterygoid plate meet, right side.
InfraOrbForamenSupL	Most superior point on the border of the infraorbital foramen, left side.
InfraOrbForamenSupR	Most superior point on the border of the infraorbital foramen, right side.
MaxillaryTuberosity	Most posterior point of the alveolar crest below the palatine suture.
Nasion	Point located where the internasal and nasofrontal sutures meet.
OpticForamenInfL	Most inferior point on the border of the optic foramen, left side.
OpticForamenInfR	Most inferior point on the border of the optic foramen, right side.
OrbitFrontoNasalL	Point at the medial border of the orbit where the frontal and nasal sutures meet, left side.
OrbitFrontoNasalR	Point at the medial border of the orbit where the frontal and nasal sutures meet, right side.
OrbitInfL	Most inferior point of the orbit, left side.
OrbitInfR	Most inferior point of the orbit, right side.
OrbitSupL	Most superior point of the orbit, left side.
OrbitSupR	Most superior point of the orbit, right side.
PalatalIntersectionPoint	Midline intersection of palatal and palatine sutures.
Prosthion	Point located where the maxillary alveolar process projects most anteriorly in the midline of the maxilla.

Rhinion	Point at the lower end of the suture between the nasal bones.
SuperiorPterygoPalatinL	Most inferior point of the area where the palatine and the lateral pterygoid plate meet, left side. Is also the most postero-inferior point of the pterygopalatine fossa.
SuperiorPterygoPalatinR	Most inferior point of the area where the palatine and the lateral pterygoid plate meet, right side.
ZygomaxillareL	Point at the inferior end of the zygomatic suture, left side.
ZygomaxillareR	Point at the inferior end of the zygomatic suture, right side.
CapexL	Point on the apex of the left canine.
CapexR	Point on the apex of the right canine.
C-P3L	Point at the alveolar crest between C and P ³ , left side.
C-P3R	Point at the alveolar crest between C and P ³ , right side.
M1-M2L	Point at the alveolar crest between M ¹ and M ² , left side.
M1-M2R	Point at the alveolar crest between M ¹ and M ² , right side.
M2-M3L	Point at the alveolar crest between M ² and M ³ , left side.
M2-M3R	Point at the alveolar crest between M ² and M ³ , right side.
P3-P4L	Point at the alveolar crest between P ³ and P ⁴ , left side.
P3-P4R	Point at the alveolar crest between P ³ and P ⁴ , right side.
P4-M1L	Point at the alveolar crest between P ⁴ and M ¹ , left side.
P4-M1R	Point at the alveolar crest between P ⁴ and M ¹ , right side.

On the mandible

CoronoidProcessL	Most posterior point on the coronoid process, left side.
CoronoidProcessR	Most posterior point on the coronoid process, right side.
Gnathion	Most inferior point of the mandible in the midline.
GonionL	Most inferior, posterior and lateral point on the angle of the mandible, left side.
GonionR	Most inferior, posterior and lateral point on the angle of the mandible, right side.
Infradentale	Highest anterior point between the central incisors.
MentalForamenL	Most anterior point on the border of the mental foramen, left side.
MentalForamenR	Most anterior point on the border of the mental foramen, right side.
SuperiorAnteriorRamusL	Most superior and anterior point on the anterior ramus, left side.
SuperiorAnteriorRamusR	Most superior and anterior point on the anterior ramus, right side.
CapexR	Point on the apex of the right canine.
C-P3R	Point at the alveolar crest between C and P ₃ , right side.
I1-I2L	Point at the alveolar crest between I ₁ and I ₂ , left side.
I1-I2R	Point at the alveolar crest between I ₁ and I ₂ , right side.
I2-CR	Point at the alveolar crest between I ₂ and C, right side.
M1-M2L	Point at the alveolar crest between M ₁ and M ₂ , left side.
M2-M3L	Point at the alveolar crest between M ₂ and M ₃ , left side.
M2-M3R	Point at the alveolar crest between M ₂ and M ₃ , right side.
P3-P4R	Point at the alveolar crest between P ₃ and P ₄ , right side.
P4-M1L	Point at the alveolar crest between P ₄ and M ₁ , left side.